

UNIT-II

HHP-1

DATE B.Pharm 1st sem

UNIT-II

SKELETAL SYSTEM

A Bone is made up of several bone tissue the system is composed of connective tissue including bones, cartilage, tendons, ligaments, and other tissue like dense, epithelium, adipose & nervous tissue.

✓ Nutrients are provided to the system through blood vessels that are contained within central canals of the bone. The skeletal system stores minerals, fats & produce blood cells.

Osteology - It is the ^{branch} of science that deals the bones of the skeletal system their structures and functions.

function of skeletal system:-

- 1) Support:- It serves as the structural frame work, support soft tissues and provides attachment for the tendons of most skeletal muscles.
- 2) Protection:- The skeleton protects the internal organs from injury e.g - Cranial bones protect the brain, vertebral protect the spinal cord and thoracic cage protects the heart & lungs.
- 3) Assists movement:- Most skeletal muscles attach to bones and bring about movement by pulling due to their contraction.
- 4) Mineral Homeostasis:- Bone tissue stores several minerals especially Ca^{++} & phosphorous, which contribute to the strength of bone.
- 5) Blood Cell Production:- Blood cells are produced in the bone marrow. Bone marrow is the tissue occupying the center of large bones. There are two types of bone marrow.
 - Red Bone marrow
 - Yellow Bone marrow.

DATE _____

Red Blood Cells, platelets and most WBC's develop in Red Bone Marrow. Some of WBC's develop in White Bone Marrow.

c) **Triglyceride: (YBM):** - Consists mainly of adipose cells, which store triglycerides, which are a potential chemical source of energy reserve.

Structure of Bone: - Bone structure may be analysed with the help of a long bone such as the Humerous. A typical bone consists of following parts.

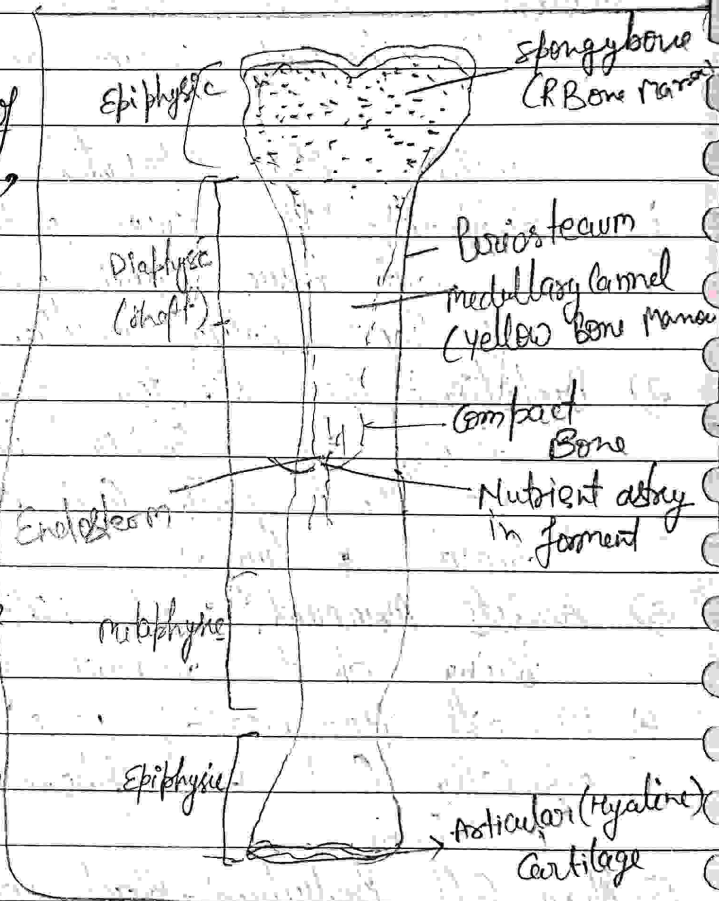
i) **Diaphysis:** - (Growing btw)

It is the body or shaft of bone which is long cylindrical, main portion of the bone.

ii) **Epiphyses:** - (growing over)

These are the distal & proximal end of the bone.

iii) **Metaphysis:** - Region b/w the diaphysis & epiphysis. There are the region of mature bone where the diaphysis joins the epiphyses. In growing bone it represents the epiphyseal plate.



iv) **Articular Cartilage:** - It is a thin layer of hyaline cartilage covering that part of epiphysis where the bone articulates with another bone. It reduce friction & absorbs shocks at freely movable joints.


DATE _____

- v) Periosteum:- It is a tough sheath of dense Irregular Connective tissue that surrounds the bone surface where there is no cartilage. Its bone forming cells enable bone to grow in thickness but not in length. Periosteum also protects the bone & serves as an attachment point for ligaments and tendons. Its attachment to underlying bone is through perforating fibres, thick bundles of collagen fibres extending into the extracellular bone matrix.
- vi) Medullary Cavity (Marrow Cavity):- It is the space within the diaphysis that contains fatty YBM in adults.
- vii) Endosteum:- Thin membrane that lines the medullary cavity. It contains a single layer of bone forming cells & a small amount of connective tissue.

Types of Bones:-

All bones of body can be classified into five main types based on shape, long, short, flat, irregular & sesamoid.

Bones Types



- i) Long Bones:- They have greater length than breadth, consist of a shaft and a variable number of end & slightly curved for strength, long bones consist mostly of compact bone tissue in their diaphyses but have considerable amount of spongy bone tissue in their epiphyses.
- e.g :- femour (thigh bone) ulna & radius (Fore Arm)
 Tibia & fibula (long bone) Phalanges (Finger & toes)
 Humerous (Arm bone)

DATE _____

2) Short Bones:- These are cube shaped & nearly equal length and width, they consist of spongy bone tissue surrounding by a thin layer of compact bone tissue.
e.g. → Carpal (Wrist)
Tarsal (Ankle)

3) Flat Bones:- They are generally thin and composed of two nearly parallel of compact bone tissue end-closings & thin layer of spongy bone tissue.
e.g.:- Cranial bones, the sternum, (Breast bone)
Ribs
Scapula.

4) Irregular Bone:- They have complex shape and vary in the amount of spongy & compact bone tissue.
e.g. vertebrae (Back Bone) Facial bones
Hip bones Calcaneus.

5) Sesamoid Bones:-

(Bone like sesame seed) Develop in certain tendons where there a considerable friction, tension and physical stress, such as palms & soles
(few mm in size)

They protect tendons from excessive wear tear
eg:- To Patella (Knee Caps).

DATE _____

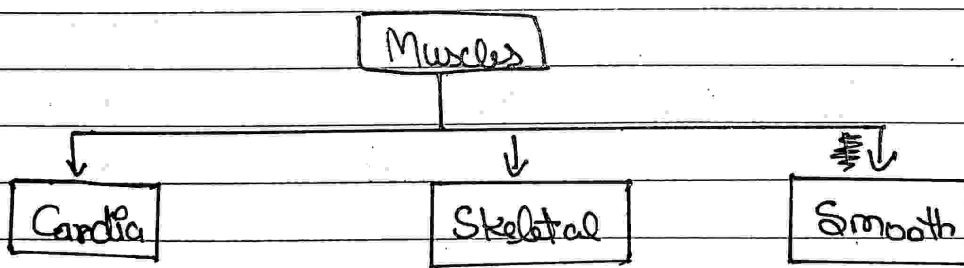
Organisation of Skeletal Muscles

- Skeletal muscles are muscles which attached to the skeleton.
- Human body contains near about 650 muscles, & 40-60% of human body mass.
- Skeletal muscles are mainly responsible for locomotion & voluntary contraction & relaxations.

functions :-

- Movement of materials along internal tubes.
- Controlling valves & body openings.
- Production of heat.
- Support the internal organs.
- Upright posture.
- Locomotion.
- Balancing on legs.

* Three types of muscles in the human body.




* Muscles are attached to bones, cartilages, ligament, skins & other muscles by fibrous structures called tendons & aponeurosis.

* Tendon is cord like structures whereas aponeurosis is a strong fibrous sheet.

* Muscles are richly supplied by blood vessels & nerves.

DATE _____

Components:-

* Skeletal muscles are composed of clusters of muscle cells.

- Muscle fibres
- Myofibers
- Myocytes

⇒ A muscle consists of packages of muscle cell called fascicles.
 ⇒ A muscle cell is long and spindle shaped.

Cell structure:-

- Muscle cell contain many nuclei
- The plasma membrane → Sarcolemma.
- The cytoplasm → Sarcoplasma.

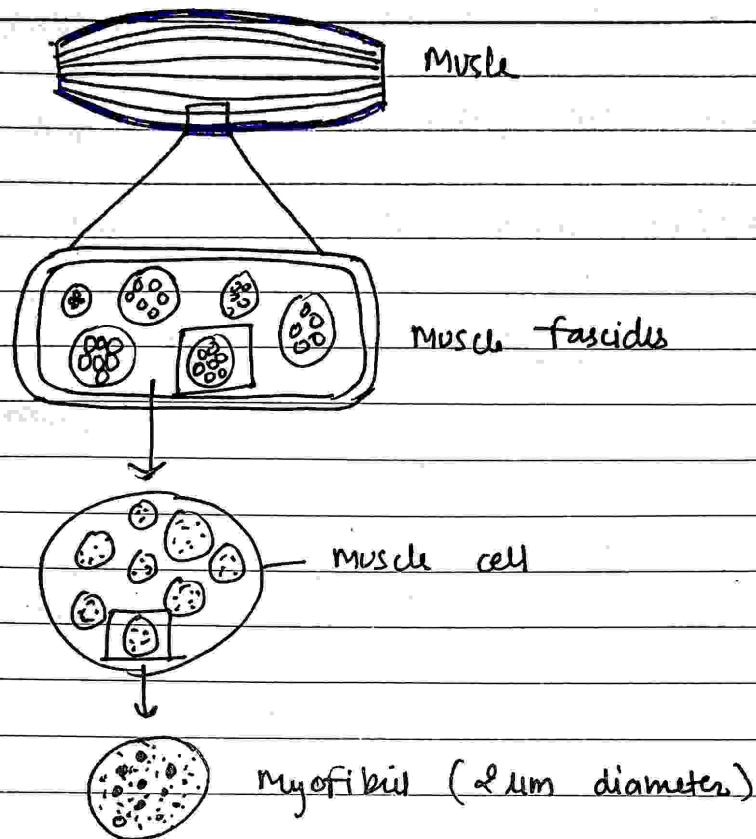
Size - length ⇒ Ranges from 0-1cm to more cm in length.

Diameter ⇒ Ranges from 0.001cm to 0.01 cm in diameter.

Myofibrils:-


- Elongated protein molecules.
- Aligned in parallel arrangements.
- Extend the full length of the cell.

DATE _____



- The myofibril consists of protein chains called Myofilaments.
- Myofilaments:- Myofilaments consists of or have a symmetrical alternating pattern of thick & thin elements
- Thin myofilaments → It consists of large no. of bundled myosin-molecules aligned in overlapping ways.
- Hexameric proteins with two identical heavy chains & two pairs of different light chains.
 - Regulatory light chain (RLC)
 - Essential light chain (ELC)

Thin
Myofilaments.



Thin filaments
8mm diameters
1-2cm long

Myosin head

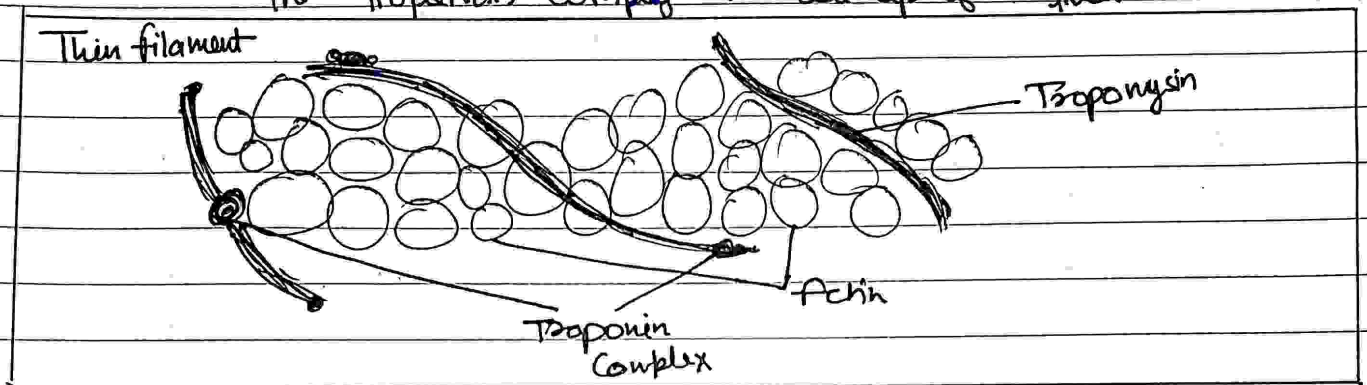
DATE _____

The thin myofibrilament (f-actin, filamentous actin)

It is made up of two helically intertwined chain (G-actin) (globular actin)

other proteins that bind to the actin molecules.

- Troponin
- The troponin complex → Made up of three subunits.



Muscle protein → 3 types of protein.

- i) Contractile :- Helps in contractions.
- ii) Regulatory :- Helps in regulation of contraction by switching & shutting the process.
- iii) Structural :- It keeps thick & thin filaments in proper alignment & responsible for myofibril elasticity & extensibility.


DATE _____

Physiology of Muscle Contraction

A) Sliding filament Mechanism of Muscle Contraction:-

- The length of skeletal muscle shortens during contraction because the thick & thin filaments slide over one another, The process is known as sliding filament mechanism.
- The thick filament contains 300 myosin molecules.
- It contains two parts.

- 1) Myosin tail
- 2) Myosin head.



- Myosin tail forms the shaft of the thick filament and heads project.
- Thin filament contain actin, tropinin & tropomyosin.
- At the onset of contraction, the sarcoplasmic reticulum release calcium ions into cytosol.
- They bind to tropinin & cause tropinin - tropomyosin complexes to move away from binding on actin.
- Once the binding sites are free, the repeating sequence of events of the contraction cycle occurs that causes the filaments to slide on each other.

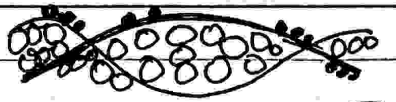
The contraction cycle consists of 4 steps:-

- 1) ATP Hydrolysis
- 2) Attachment of Myosin to actin to form cross-bridges
- 3) Power stroke
- 4) Detachment of myosin from actin.

10

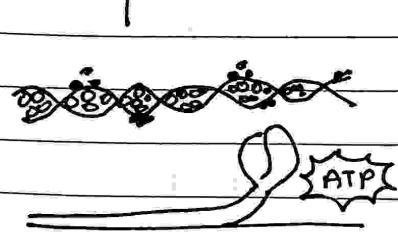
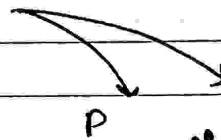
① Myosin head split

ATP and become reoriented & energized



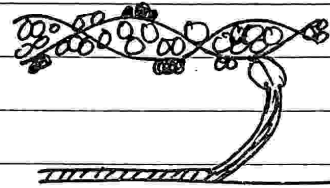

②

Myosin heads bind to actin forming cross bridges.



Contraction cycle continues if ATP is available & Ca^{2+} level in the sarcoplasm is high

④ As myosin heads bind ATP, the cross bridges detach from actin



③

Myosin heads rotate towards centre of the sarcomere (Power stroke)

[Sliding filament Mechanism of Muscle Contraction]

- I) Impulse arrives at neuromuscular junction.
- II) Ca^{2+} released from sarcoplasmic reticulum.
- III) Calcium ion diffuse through sarcoplasm.
- IV) Ca^{2+} attach to troponin causing it to move.
- V) As a result tropomyosin on actin filament moves.
- VI) Myosin binding sites on actin filament are exposed.
- VII) Myosin head bind to the actin filaments forming cross-bridges.
- VIII) $ADP \times Pi$ are released from the myosin head.
- IX) Myosin changes shape resulting in myosin head nodding forward.
- X) Myosin result - actin filaments sliding over each other.
- XI) ATP binds to the myosin head (XII) This causes the myosin head to detach from the actin.
- XII) ATP is broken down to $ADP \times Pi$ by ATPase on the myosin head.

(11)

DATE _____

- xiv) Myosin change shape, resulting in head returning to upright position.
- xv) ATP is used to actively transport Ca^{2+} back into the sarcoplasmic reticulum.

Neuromuscular Junction

A neuromuscular junction is a synapse b/w a motor neuron & skeletal muscle. This event of synaptic transmission leading to contraction & relaxation of skeletal muscle.

Nerve impulse arrives at axon terminal of motor neuron & triggers release of Acetylcholine (ACh)

↓

ACh diffuse across synaptic cleft binds to its receptors in the motor end plate & triggers a muscle action potential.

↓

Acetylcholinesterase in synaptic cleft destroys ACh so another muscle action potentials does not arise unless more ACh is released from motor neuron

↓

Muscle action potential travelling along transverse tubule open Ca^{2+} release channels in the sarcoplasmic reticulum (SR) membrane, which allow calcium ion to flood into sarcoplasm.

↓

Ca^{2+} binds to troponin on thin filament, exposing the binding sites of myosin

↓ elevated Ca^{2+}

Contraction; Power strokes ~~use~~ use ATP; myosin head binds to actin release, thin filaments are pulled toward centre of sarcomere

↓

(12)

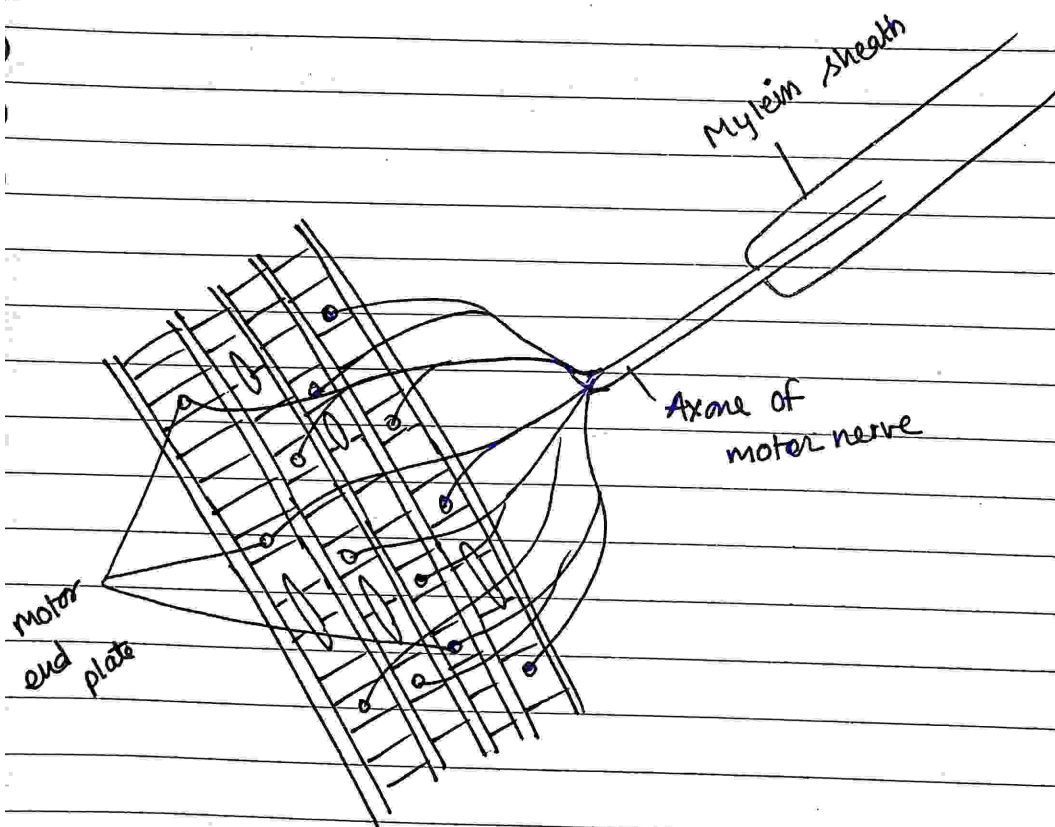
DATE _____

↓
 Ca^{2+} release channels in SR close Ca^{2+} & active transport pumps use ATP to ~~release~~ restore low level of Ca^{2+} in sarcoplasm.

↓
 Ca^{2+} active transport pumps

↓
 Troponin - Tropomyosin complex slides back into position where it blocks the myosin binding site on actin

↓
 Muscle relaxes



Neuromuscular Junction

U-IIIrd

JOINTS

Joints

DATE: _____

Joint (or articulation) - The Junction b/w two or more bones. with the exception of hyoid bone, every bone in the body is connected to or forms a joint. There are 230 joints in the body.


Definition -> A joint is location at which two or more bones make contact

- they are constructed to allow movement and provide mechanical support and are classified structurally & functionally
- Structural classification is determined by how the bones connect to each other, while functional classification is determined by the degree of movement b/w the articulating bones.

functions

- Hold the skeletal bones together
- Allow the skeleton some flexibility so gross movement can occur.
- Make bone growth possible.

(classified of joints (structural classification))



I) Fibrous / Immovable / fixed -> There is no synovial cavity & bone are connected by dense connective tissue consisting mainly collagen.


It also divided into three types

- i) Sutures
- ii) Syndesmosis
- iii) Gomphosis

ARTICULATIONS

DATE _____

(i) Sutures/Synostosis → Sutures are found b/w bone of the skull. In fetal skulls sutures are wide to allow the movement during birth. The later become rigid (synarthrodial).

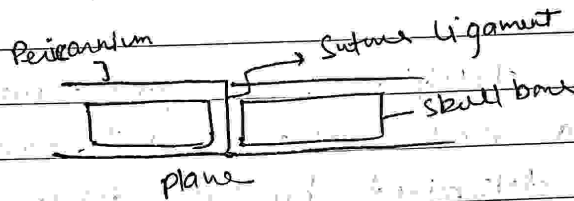


Sutures b/w the bone of cranium

Structure of the skull

Type 3

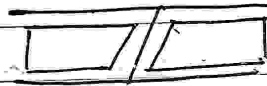
i) Plane suture



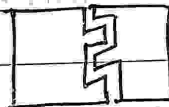
ii) Serrate suture




iii) Squamous suture



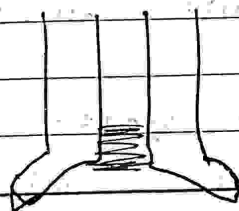
iv) Denticulate suture



v) S chindylis suture



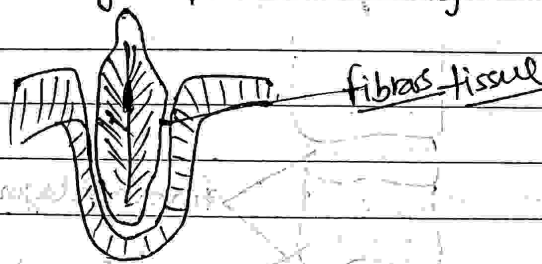
(ii) Syndesmoses → Syndesmosis joint where two adjacent bones are linked together by a considerably greater amount of connective tissue than in suture in form of interosseous ligament membrane.



[Tibiofibular Syndesmosis]

DATE _____

Gomphosis → It is a specialized fibrous joint restricted to fixation of teeth in alveolar sockets of the maxilla or mandible. The root of tooth is attached to the socket with alveolus by periodontal ligament.



II) Cartilaginous → Cartilaginous are connected entirely by cartilage.

Cartilaginous joint allow more movement b/w bones than a fibrous joint but less than the highly mobile synovial joint.

• The cartilaginous joint also lack the joint cavity.

• Cartilaginous joints are those joints in which the bone forming joints are united by means of either hyaline cartilage & fibro cartilage

→ These are of two types

① Primary (Synchondrosis)

② Secondary (Symphysis)

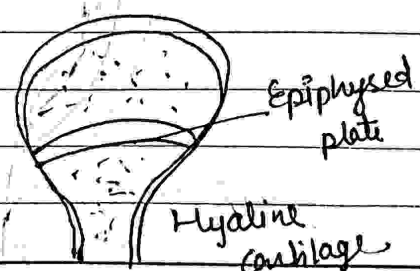
I) Primary (Synchondrosis) Cartilaginous →

→ Bones forming joint connected by a plate of hyaline cartilage

→ These joints are immovable & mostly temporary in nature. This cartilage may ossify with age

eg → Joint b/w 1st rib & manubrium of the sternum

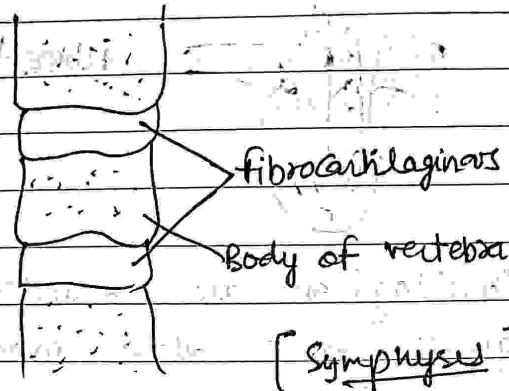
* Joint b/w epiphysis & diaphysis of growing long bone



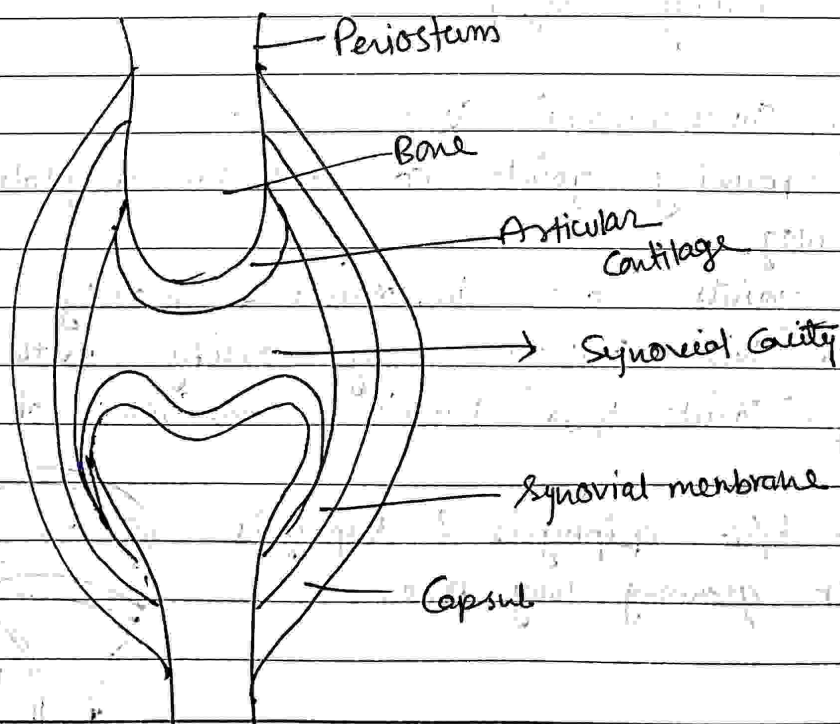
DATE _____

ii) Secondary / Symphysis :-

In these joints the articular surfaces of bone forming the joints are covered by thin plates of hyaline cartilage which are connected by fibrocartilage.



III) Synovial Joints → These joints possess a cavity & more than articular ends of bones forming the joints are enclosed in fibrous capsules. As a result they are separated by a narrow cavity, the articular cavity which is filled with a fluid called synovial fluid. The synovial fluid is like an egg albumin, hence name synovial joints.

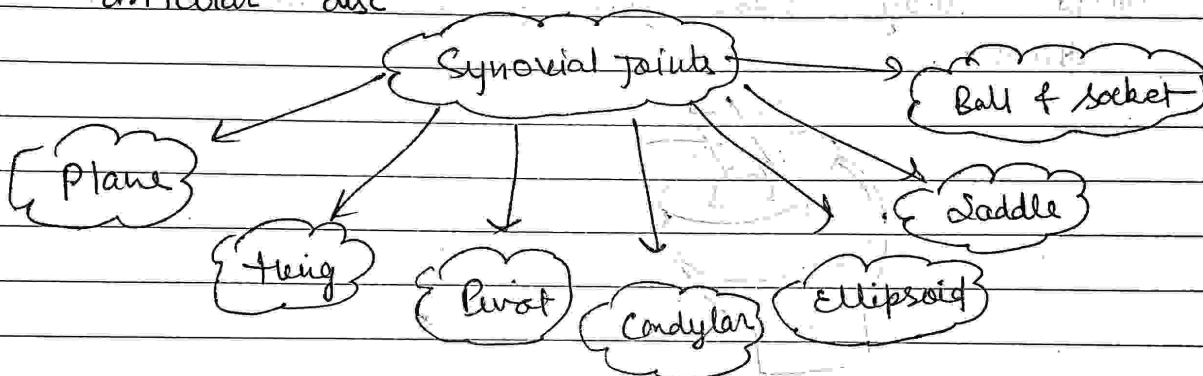


Synovial joints

DATE _____

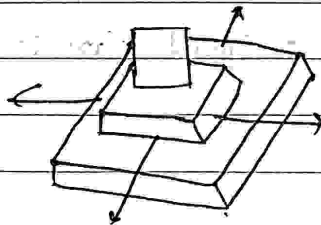
Characteristic features

- The articular surfaces, are covered by a thin plate of hyaline cartilage
- The joint cavity is enveloped by an articular capsule which consist of outer fibrous capsule & inner synovial membrane
- The cavity joint is lined everywhere by synovial membrane except over articular cartilage
- The cavity is filled with synovial secreted by synovial membrane which provide nutrition to articular cartilage & lubrication
- Some joint cavity completely or incompletely divided by articular disc

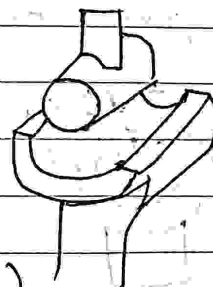


(i) Plane joint → Articular surfaces are more or less flat, they permit gliding movement in various direction.


eg → Inter carpal joints, Inter tarsal joints



(i)



(ii)



ulna

(ii) Hing joint → The articular surfaces are pully shaped. The type of joint permits movement in one plane around transverse axis.

This movement consists of flexion & extension

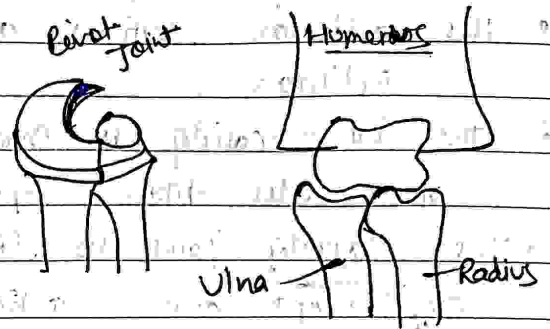
eg → Elbow joint, knee joints, ankle joints

DATE _____

iii) Pivot joint →


Surfaces of bone is rounded & fits into concavity of another bone.

Rounded part is surrounded by ligamentous ring movement is limited to the rotation around central axis.



eg → Joint b/w proximal end of the radius & ulna

iv) Condylar joint → The surface of bone fit into socket, the end of bone bearing cond articular surface called condyle these joints permit movement in two direction.

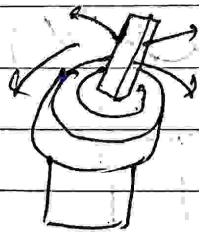


v) Ellipsoidal joint →

Elliptical convex surface of one bone articulates with elliptical surface of another bone.

The movement are permitted in two direction.

eg - wrist joint, atlanto occipital joint.




Ellipsoidal joint

DATE _____

vi) Saddle joint →

The articular surfaces are reciprocally saddle shaped i.e. concavo-convex. This unique articulation is modified condyloid joint that allow wide range of movement.

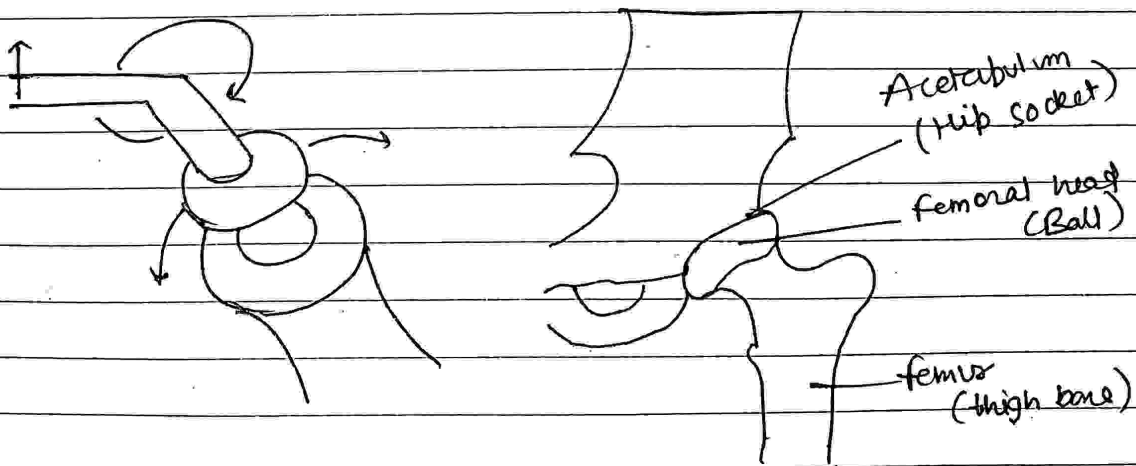
eg → Joint b/w Trapezium & metacarpal bones of the thumb. Sternoclavicular joint.

vii) Ball & Socket joints →

It consists of a bone with a ball shaped head that attaches with the cup shaped cavity of another bone. The type of joints allows for a wider range of motion than any the kind.


• It permits movement in all planes and a rotational movement around a central axis.

eg → Hip, Shoulder joint & incudostapedial joint.



DATE _____

(B) functional classification of Joints



- i) Synarthrosis → Synarthrosis permit little or no mobility.
Most synarthrosis joints are fibrous joint
eg → Cranial suture in adults.
- ii) Amphiarthrosis → It permit slight mobility. The two bone surface at the joints are both covered in hyaline cartilage and joined by strand of fibrocartilage.
eg → Cartilaginous joints.
- iii) Diarthroses → Permit a variety of movement.
only synovial joints are diarthroses.